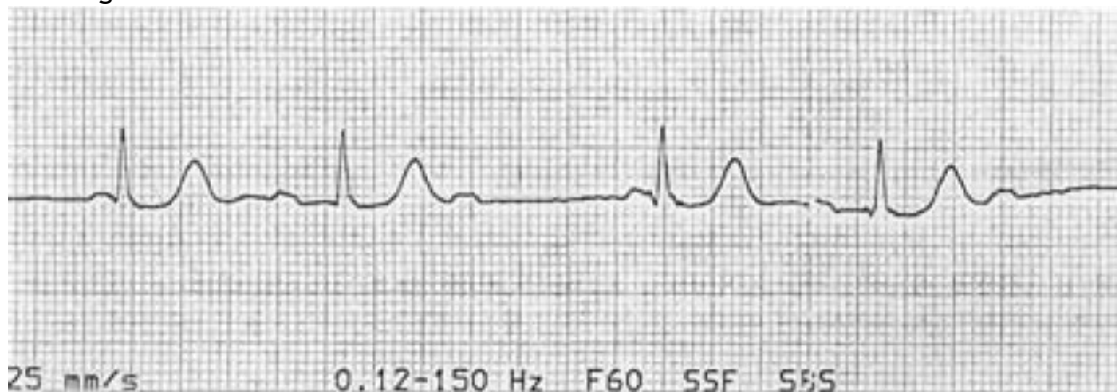

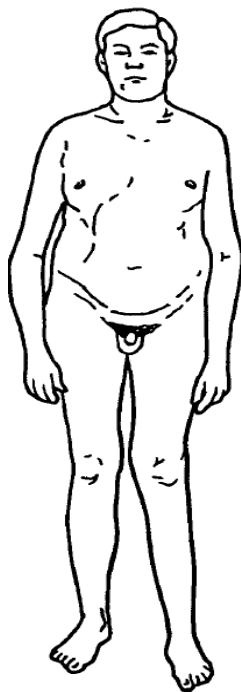
## NEET PG SAMPLE QUESTIONS

- Q-1 A 65-year-old man with diabetes, on an oral hypoglycemic, presents to the ER with a sports-related right shoulder injury. His heart rate was noted to be irregular and the following ECG was obtained.




The best immediate therapy is

- a. Atropine      b. Pacemaker      c. Digoxin      d. Observation
- Q-2 The patient pictured below presents with gynecomastia and infertility. On exam, he has small, firm testes. Which of the following is correct?



- a. The patient is likely to have low levels of gonadotropins  
b. The patient has Turner syndrome  
c. His most likely karyotype is 47 XXY  
d. The patient will have normal sperm count and testosterone

Q-3 Retinitis pigmentosa is a hereditary disorder, which affects the photoreceptors (the rods and the cones) in the retina. These photoreceptors are located in which of the numbered layers in Fig



?

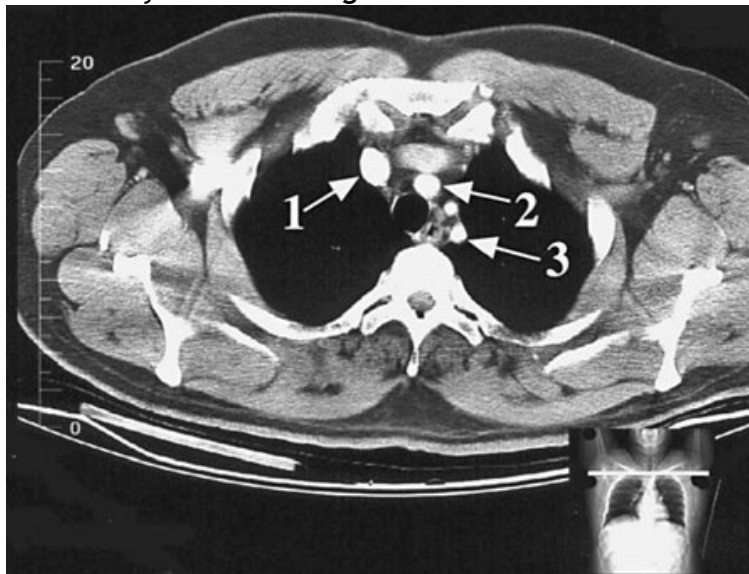
a. 2

b. 3

c. 4

d. 5

Q-4 The structure indicated by arrow 1 in Fig is which



vessels?

a. Brachiocephalic artery

b. Left brachiocephalic vein

c. Left common carotid artery

d. Right brachiocephalic vein

Q-5 Which of the following syndromes do not constitute 'Stroke' as per WHO definition :-

a. Transient ischaemic attack (TIA)

b. Subarachnoid haemorrhage

c. Hemiplegia

d. Monoplegia

